



Volume 9: Issue 1 Fall 2013

## Service Builds Beneficial Relationships

By Alison LaCarrubba, DVM

**T**he equine ambulatory program is in its 12th year and I find myself speaking of the program with such pride in our services and capabilities. We have a busy, full-service practice that allows for optimal training for our up-and-coming veterinarians, as well as optimal care for our clients. Our client base has grown tremendously and we adore visiting with friends and fellow horse owners as we perform routine and emergency work.

We are also excited to welcome Dr. Alicia Foley. Foley recently finished a residency and is working in both the ambulatory program and the internal medicine service in the clinic. She brings with her expertise in internal medicine with a special interest in foals and gastrointestinal disease.

The clinic is currently under construction installing a state-of-the-art magnetic resonance imaging (MRI) system. This will be the only MRI of its kind in the central United States. This will allow us to better image and diagnose subtle soft tissue injuries of our equine athletes.

The ambulatory program continues to foster a relationship with Longmeadow Rescue Ranch with very many thanks to our dean who has fully supported this endeavor. Each month we send one clinician, one intern and two cars full of students to work on the Longmeadow horses. This relationship has been a win-win situation. We are able to introduce our students to all aspects of equine care, including preventive care, dentistry, lameness and basic surgeries, and in return the horses of Longmeadow benefit from our services. I am very proud to be a part of this relationship.

---

***The mission of our equine ambulatory service is to provide the highest standard of medical and surgical care to our patients while training the next generation of veterinarians.***

---

More recently our program has branched out to Fairmount Track in Illinois. Drs. Martha Rasch and Shannon Reed travel to the racetrack on alternate Mondays, allowing our students to gain tremendous knowledge and experience relative to the racing thoroughbred. Common therapies performed at the track include lameness examinations, and joint injections as well as newer therapies such as stem cell injections and platelet rich plasma administration.

Over the last year as I've taken on more in-house clinical duties, it has forced me to examine the various aspects of my appointment. My time is divided between managing critical, emergent cases requiring in-depth knowledge and diagnostics in the clinic, balanced with ambulatory duties, which certainly presents its case challenges, but allows me to develop the long-term relationships with clients that gives me true job satisfaction. After 10 years together I realize I've seen many of you, your families and your horses grow.

What I did not realize as a new veterinarian that I now realize is how important these relationships are and how much they mean to me. There has never been a doubt about my love of the profession, but the friendships I have built over the years have given me the greatest joy and job satisfaction. Thank you for that, and thank you for your continued support.

# Ambulatory Team Welcomes New Interns

## Alison LaCarrubba, DVM

**D**r. Alison LaCarrubba, originally from New York, graduated from the University of Missouri College of Veterinary Medicine in 2001. LaCarrubba completed an internship in equine medicine and surgery at the University after graduation and subsequently spent a year working in an equine exclusive private practice. She returned to the University in July 2003, and in 2009 she completed the credentialing process for the American Board of Veterinary Practitioners in Equine Practice and is now focused on becoming more specialized in equine dentistry.



This year marks LaCarrubba's 10th anniversary with the Veterinary Medical Teaching Hospital. She recently increased her time working with the internal medicine service and is spending fewer months per year in the truck, although she remains committed to the ambulatory program, as well as growing both the ambulatory and in-house dental programs. Over the past couple of years LaCarrubba has attended a variety of advanced dental training courses and looks forward to using her new skills to diagnose and treat routine and complicated dental issues facing the horse.

## Martha Rasch, DVM

**D**r. Martha Rasch is a clinical instructor at the MU College of Veterinary Medicine and focuses on the equine ambulatory practice. Rasch was born in Chicago and grew up riding hunters and jumpers in St. Louis. She began to ride in three-day events in college. After earning a DVM at MU, she completed a rotating equine internship at the University. She continued on to work as a clinical instructor for the equine ambulatory service.



She spends the majority of her time instructing senior veterinary students while traveling to work on horses within the Columbia area. She has also been traveling weekly to Fairmount Park in Illinois, extending our ambulatory services by offering routine care, advanced lameness and imaging diagnostics to the racehorse population there. She is particularly interested in wound management as well as

critical care in the ambulatory setting. Rasch works closely with the referral clinicians in the MU Equine Clinic to provide superior care to horses.

## Alicia Foley, DVM

**D**r. Alicia Foley has recently joined our team as a post-doc, working both with the equine internal medicine and equine ambulatory services. Foley grew up on a wheat farm in Goddard, Kan. She earned her bachelor's degree in western equestrian studies at the University of Findlay in Findlay, Ohio. Upon graduation Foley spent three years in New York State as a breeding manager and assistant trainer on a reining horse farm. She earned her DVM in 2009 from Kansas State University in Manhattan, Kan. She then completed a rotating equine internship at Equine Sports Medicine and Surgery in Weatherford, Texas. Prior to joining the faculty at MU she completed an equine internal medicine residency at Marion duPont Scott Equine Medical Center in Leesburg, Virginia where she researched the effects of aerosolized hyperimmune plasma on *Rhodococcus equi*, a cause of foal pneumonia. Her professional interests include: high risk pregnancy, neonatal critical care, neurologic disease, and gastrointestinal disease. In her free time she enjoys gardening, riding reining horses, and competing in agility with her two Australian shepherds, Dodge and Pirata.



**O**ur interns have a special interest in working with horses, and potentially going on to complete a residency, specializing in either equine medicine or equine surgery. Every June we welcome a new crop of interns. This year our interns include Dr. Elizabeth Hochreiter, Dr. Ashley Navin and Dr. Jamie Zimmerman.

## Elizabeth Hochreiter, DVM

**D**r. Elizabeth Hochreiter grew up in Erie, Pa. She graduated from James Madison University in 2008 before attaining her DVM from Ross University in January 2013. She completed her clinical training at Oklahoma State



Continued on page 3



University. During spring of 2013, she worked as an intern in a private mixed practice in northern Virginia (small animal and equine ambulatory). Her veterinary interests include equine medicine, and equine ophthalmology in particular.

She grew up riding show hunters and now mainly rides for pleasure. Her thoroughbred mare Missy has moved with her across the country from Pennsylvania to Virginia, Oklahoma and now Missouri! Hochreiter aspires to work at a full service equine practice after completion of her internship.

### Ashley Navin, DVM

**D**r. Ashley Navin grew up on a small horse farm in central New Jersey spending most of her time playing outside and riding horses. She received her bachelor of science degree in animal science from the University of Delaware and her VMD from the University of Pennsylvania.



She has always had a strong love for horses and is particularly interested in internal medicine and equine reproduction. In her spare time she still loves to go out on long trail rides with her horses and hiking with her dogs. Navin aspires to work at a full-service equine practice after completion of her internship.

### Jamie Zimmerman, DVM

**D**r. Jamie Zimmerman grew up on her parent's dairy farm in Wisconsin. She obtained her first horse when she was 10 years old and has since had numerous others. Growing up Jamie participated in western speed events (barrels and poles), but more recently she enjoys trail riding when she is able to get home. Zimmerman currently owns a 28-year-old Arabian gelding and a 10-year-old Morab mare, along with numerous cats and dogs. She attended the University of Wisconsin-Madison for her undergraduate and veterinary degrees and graduated in 2012. She then completed an equine internship at the Morrie Waud Equine Clinic, an equine surgery and emergency referral center, in southern Wisconsin. This solidified her interest in surgery and she hopes to complete a large animal surgery residency after her internship.



## Synovial Structures Vulnerable to Injury

*By Jamie Zimmerman, DVM*

**I**njuries to the distal limb of horses are a common occurrence with potentially serious complications. While many injuries are superficial and heal without problem, some injuries involve synovial structures and require further treatment. The synovial structures (joint or joint-like) in the lower limb include the navicular bursa, coffin joint, pastern joint, fetlock joint, and digital flexor tendon sheath. These structures are vulnerable to injuries of the distal limb and are more likely to become infected due to environmental exposure and limited coverage. If a synovial structure is contaminated during an injury, this becomes a life-threatening problem for the horse that must be addressed immediately.

**W**hen a penetrating injury or a significant laceration occurs over a joint or other synovial structure there is a significantly better prognosis if treated early and aggressively. In this situation every hour counts. Typically, horses with an infected joint or synovial structure will be extraordinarily painful, and either minimally weight bearing or non-weight bearing. Other common signs of joint/synovial involvement include marked swelling of a specific joint and heat. Aggressive cleaning of the area will reduce the bacterial numbers on the surface of the wound. If the wound is close to a joint/synovial structure a sample of fluid will be taken from the joint and analyzed to make an accurate diagnosis and provide information necessary for optimal treatment. Other diagnostics, such as radiographs and ultrasonographic examination, are frequently utilized to make a complete diagnosis.

**I**f a joint or synovial structure has been penetrated and is infected it is important to carefully consider all treatment options. The most favorable option would be to refer the horse to a specialist, anesthetize the horse, and

Continued on page 4

# Horse Battles Injury on Heels of Illness

## Case Study

**P**aco is a 14 year old Missouri Fox Trotter gelding who has is a long-time client of the equine ambulatory service. We have visited with Paco many times over the years for routine and emergency care. Paco has a tremendous personality and an incredibly committed owner who cares for him. In the early spring of this year Paco was diagnosed with laminitis (founder), which is inflammation of the sensitive tissues of the hoof and becomes a common problem in mid-Missouri when the grass is lush. We treated Paco with shoeing modifications, stall rest, a weight loss program and supportive care and he responded nicely. Unfortunately, the day after Paco was given a clean bill of health, he was involved in a pitch fork accident. The pitch fork penetrated the back of his right hind pastern, affecting not only the digital tendon sheath, but the tendon itself. Paco was initially examined in the field for a minimally weight bearing lameness, as well as the puncture. A complete the set of radiographs were taken and an ultrasound examination with the portable field unit was performed. Based on our findings it was determined that penetration and subsequent infection of the sensitive synovial structures of the hind limb was likely. We



Paco has not recovered from his serious infection enough to be ridden, but he is once again enjoying a good quality of life.

knew immediately that this could be a life threatening condition for Paco.

**A**fter further evaluation at the Veterinary Medical Teaching Hospital (VMTH) Paco was taken to surgery. While in surgery it was determined that Paco did in fact have an infected digital tendon sheath, significant damage to his deep digital tendon, and small bone fragment off of the back of the pastern. The digital tendon sheath is a synovial structure which wraps around the tendons of the distal limb, allowing the tendons to work optimally. During the surgical procedure the affected areas were cleaned and lavaged thoroughly and Paco was started on

aggressive antimicrobial therapy, both in the tendon sheath, as well as systemically. Post-operatively the limb was bandaged and Paco was put in a shoe with an elevated heel to decrease tension on his tendon and allow for healing. Paco was sent home for long-term convalescence and physical therapy with continued antimicrobial support to ensure the area was clear of infection. Working together with Paco's very committed owner, we visited Paco numerous times over the summer, evaluated his progress and monitored his tendon healing with our portable ultrasound unit. Although Paco is not sound to ride, our goal in this case was to give Paco enough mobility and comfort that he can enjoy a life of pleasure, which he surely is doing. Paco's case was complicated and required numerous visits both on the farm as well as in the VMTH. This case displays the exemplary team work between our ambulatory unit and referral hospital that we are so proud of. With the undying support of Paco's owner we were able to turn a very bad situation around. We have all very much enjoyed working with Paco and his owner through this difficult time and we are all happy that he continues to move in the right direction.

---

Synovial, Continued from page 3

thoroughly clean the affected joint using an arthroscope. This will allow for the most definitive diagnostics and complete cleaning, giving the horse the best chance of making a complete recovery. If the injury is new and the horse is particularly cooperative, we may elect to clean the infection in the standing horse on the

farm by placing needles into the joint and flooding the joint with sterile saline. Whichever technique is used to treat the focus of the infection, the horse will also be treated aggressively with broad spectrum antimicrobials, both in the joint and systemically to gain control of the infection as quickly as possible.

**P**rognosis varies considerably depending on the specific structure involved, duration of the infection before treatment, and presence or absence of bone or tendon involvement. Success can be maximized with early identification and appropriate aggressive intervention.



# Similar Conditions Have Different Causes

By Ashley Navin, DVM

**M**any in the equine industry are familiar with the term “tying up.” It is important to realize that there are a number of different causes and an accurate diagnosis is essential in order to institute appropriate treatment and long term management. The two most common causes are recurrent exertional rhabdomyolysis (RER) and polysaccharide storage myopathy. While these disorders often have a similar presentation, there are important differences.

**R**ecurrent exertional rhabdomyolysis, also known as tying up or Monday morning disease, is a condition in horses that is characterized by stiff, hard muscles, profuse sweating and reluctance to move after exercise. Dark red to brown urine may be observed. Diagnosis is often based on clinical signs, history and measurement of muscle proteins in the blood, however a muscle biopsy may be necessary for definitive diagnosis. The exact cause of RER is unknown, but young thoroughbreds, and other light breed horses seem to be more heavily represented. Altered intracellular calcium metabolism, or other electrolyte abnormalities associated with rigorous exercise may be contributing factors. Horses with RER tend to experience episodes when they are in stressful situations or after heavy exercise. No matter what the cause, horses suffering from an acute, severe attack should be rested and often require pain management and intravenous fluids to correct dehydration and electrolyte abnormalities as well as support the kidneys. In general, to minimize future attacks, attempts should be made to limit stressful situations, along with providing ample turnout and regular exercise to the affected horse.



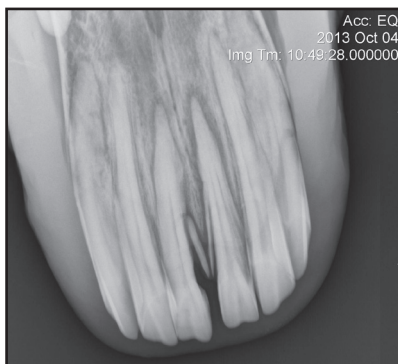
**P**olysaccharide storage myopathy (PSSM) can appear similar to RER with muscle stiffness, sweating and reluctance to move, however the cause of PSSM is quite different. PSSM is characterized by the abnormal accumulation of glycogen, a normal sugar stored in the muscle in an abnormal form. Horses can experience an episode after light exercise or even while at rest. Horses may seem lazy, have a shifting leg lameness, tremors in their flank region or show signs similar to colic after exercise. Dark red-brown urine may also be noted and in severe cases horses may become recumbent. Signs are often first noticed after initiation of training or after periods of lay-up where there has been minimal turnout. There are two forms of PSSM. Type 1 has been shown to have a genetic basis and thus can be passed down to the offspring of affected horses. This form is found in more than 20 breeds; however, it is most common in quarter horses, warmbloods and draft breeds. A genetic test does exist for this form of the disease and is recommended in any of these breeds that are showing signs of tying up. A muscle biopsy is necessary in the diagnosis of Type

2 PSSM. PSSM can often be confused with a disease called Shivers, seen most commonly in draft breeds as well. Shivers is a neuromuscular disorder with an unknown cause that results in trembling of the hind limbs when lifted or when backing the horse. It is unrelated to PSSM. Regardless of the specific form, PSSM treatments are similar. For an acute attack, exercise should be discontinued and the horse should be placed in a non-stressful environment. Medical therapy often includes anti-inflammatories and intravenous fluid administration. To prevent further episodes regular daily exercise is necessary to enhance glucose utilization, ample access to turnout, and diet modifications (high fat, low starch diet) are essential.

**W**hile these two forms of tying up appear rather similar, they are in fact quite different. Early recognition of the signs of tying up is important so appropriate treatment can be initiated. While there is not a cure for either form of the disease, accurate diagnosis can help influence changes in management that will aid in preventing future episodes and lead to a better quality of life.

# A Dental Disease of Aging Horses

In recent years a painful disorder of equine incisor and canine teeth of aged horses has been reported. Equine odontoclastic tooth resorption and hypercementosis (EO-TRH) is quite literally a mouthful. The hallmarks of the disease include pain, loose teeth, and periodontal disease, or inflammation of the supporting structures of the tooth. This disease is confined to the older population and not typically seen in horses less than 15 years of age. Interestingly, this is similar to a disease noted in both humans and cats.



Horse owners may notice that it is difficult for their horse to bite a carrot or other hard treat, or that the horse has stopped using the incisor teeth altogether toprehend their food. A definitive diagnosis can be made after a complete oral examination and radiographic evaluation of the incisor and canine teeth. Radiographs will show the tell-tale resorptive lesions as well as extensive deposits of cementum, which causes the roots to appear enlarged.

At this time there is not extensive information on the definitive cause of this disease. We suspect the disease starts out as periodontal disease and generalized inflammation and perhaps has an immune mediated component. A recent study of the disease is looking into complex bacteria involved in the human disease. These bacteria have been found in relation to EO-TRH as well and prove an interesting area of future research. The only definitive treatment of the affected and painful teeth is extraction. Each case needs to be dealt with on an individual basis. Some horses will have only a few teeth that need to be removed to start. Horses showing more advanced disease may be best served by removal of all or most of their incisor and/or canine teeth. This may sound dramatic but horses do very well without their incisors and will continue to graze and eat well when managed correctly. Typically these horses are much happier once the source of pain — the affected teeth — are removed and they go on to live a long life.

## Preventing and Managing *R. equi*

By Alicia Foley, DVM

**R**hodococcus equi is a significant cause of pneumonia and extra-pulmonary disease in foals 3 weeks to 5 months. Rhodococcus is ubiquitous in the environment and can be found in the soil. The hallmark of the disease is abscess formation within lung tissue. Foals that are affected typically have decreased appetite, lethargy, fever, and increased rate and effort of breathing. Early diagnosis can be challenging leading to the presence of severe infection before clinical signs are evident in the affected foal.

### Management

Decreased incidence of disease has been observed on farms that foal at pasture and with decreased numbers of mare and foal pairs. However, no singular change in management has been associated with decreased incidence of disease. Mares and foals both have been shown to shed virulent *R. equi* in their feces. Keeping areas clean and decreasing dust exposure may help decrease foal exposure.

### *R. equi* Pneumonia Prevention

Vaccination, prophylactic antibiotic administration, and hyperimmune plasma have all been investigated for prevention of development of disease associated with *R. equi* infection. Despite efforts to develop an adequate vaccine, neither pre-foaling vaccination of mares nor foal vaccination have been effective at disease prevention. Prophylactic antibiotic administration showed mixed efficacy and contributes to the development of resistant bacterial populations and is not recommended. Hyperimmune plasma administration after birth and at 14 days of age is the only treatment that may decrease the incidence of disease. However it is not universally effective.

### Diagnosis

Definitive diagnosis requires culture of tracheal secretions. However, presence of abscessation identified with ultrasound or radiograph in conjunction with clinical signs can lead to a presumptive diagnosis, especially on affected farms.

### Treatment

Treatment with appropriate antibiotics is necessary for clearance of the organism. The length of treatment is dependent upon severity of disease and response to treatment and can range from three to six weeks. Repeated evaluations, normally at weekly intervals, are necessary to determine when it is safe to stop treatment. Vigilant monitoring is required to identify affected foals early so adequate treatment can occur. Simple screening tools can be used to identify foals that are at risk of developing disease. Taking the temperature of foals at least once daily will help to identify if further evaluation is necessary. Foals with temperatures greater than 102F should be further examined.

# Racetrack Injuries Often Due to Overuse

By Martha Rasch, DVM

**D**rs. Martha Rasch and Shannon Reed, DACVS, have expanded the MU Equine Ambulatory practice to include equine cases at Fairmount Park, a racetrack in Collinsville, Ill. During these weekly visits, services ranging from routine preventive care to advanced lameness and diagnostics are provided. This has offered fantastic learning opportunities for clinicians and students, as we enhance our understanding of the common conditions that result from the speed work performed by the racehorse athletes. Many of you ride off-the-track thoroughbreds and may be very familiar with some of the issues that are specific to these athletes.

Just as with any high intensity sport, equine athletes deal with injuries as an unfortunate side-effect of training and competition. Most of these conditions are not the result of catastrophic accidents, but rather cumulative, long-term use issues, and include other factors such as age, gender, breeding, racing surface, training schedules, and medications.

Topping the list of affected systems, musculoskeletal injuries constitute 80-90 percent of all veterinary cases at the track. The detrimental effect of musculoskeletal issues can be felt far and wide, including loss of training and racing time, death, jockey injury, and poor public perception of the racing industry. As we strive to improve the safety and welfare of these racehorses, it is essential to understand the basic mechanisms by which many of these common injuries occur. Some of the most common injuries seen at a racetrack are as follows:

**Bucked shins** are an inflammatory condition seen on the front of the cannon bones, causing painful, raised lesions. This inflammation results from the repeated concussion of a rigorous training regimen, especially in younger horses with more flexible bones. Although the bone is responding to new activity with

appropriate remodeling, pain can occur when the exercise overwhelms the bone's ability to adapt. If severe enough, this inflammatory damage can cause bone fractures later. Rest is the most important step in treating these horses, allowing for completion of the new bone formation. Given proper rehabilitation these horses frequently return to full function.

**Splints** are new bone formations along the affected splint bone. Interosseus ligaments, a dense connective tissue, attach the splint bones to the cannon bone and can be damaged from excessive concussive or rotational forces. This damage results in painful swellings which are later stabilized by more long-standing new bone formation. Large swellings can result in long-term soundness issues by interfering with the suspensory ligament or knee function. Treatment includes rest and topical anti-inflammatory medications. These horses tend to have minor cosmetic defects but have an excellent prognosis for long-term soundness.

**Tendonitis** (bowed tendon) is inflammation of a tendon, the structures that connect muscle to bone. Although naturally elastic to create power and flexibility, inflammation and tearing can occur when these tendons are overstretched. This can result from fatigue or from abnormal forces. As a result, the horse experiences pain, swelling, and loss of function. Horses transitioning from sedentary activity to conditioning work are especially at risk for this overload damage. Any of the three main tendons that run down the back of the equine limb can be affected but the most commonly injured is the superficial digital flexor tendon (SDFT). Rest and careful rehabilitation are the core principles to recovery and can be combined with regenerative therapies such as platelet-rich plasma, shockwave, or stem cell therapy.

**Osteochondritis dessecans** (OCD) is a developmental disease of joint carti-

lage. This disease has many contributing factors including genetics, mechanical forces, and diet. As the surface of a joint develops, these factors cause instability, pain, and inflammation. The sheering forces placed on joints like the hock, stifle, fetlock, and shoulder can dissect pieces of cartilage leading to joint inflammation and lameness. Many of these lesions can be repaired surgically, if caught before considerable damage occurs. If horses are allowed to run on this irregular joint surface for too long, arthritis and long-term damage will occur.

**Skeletal fractures** are one of the most devastating injuries seen at the race course. On a straightaway, a horse's leg is loaded with three times its body weight; this increased to between five and 10 times the body weight when turning. This repetitive impact can produce microscopic cracks that, when not allowed to heal, can lead to weakening of the bones and eventual fractures. Most of these fractures result in small fragments but some can be more devastating. Currently, the American Association of Equine Practitioners recommends at least 10 days between races to allow for repair of this micro-damage. However, when major damage occurs, many of these broken bones can be repaired with casting or bone plates.

The industry as a whole has recognized the need to reduce injuries that occur in our racehorse athletes. The dramatic physical, emotional, and financial effect of these injuries is felt at all levels of the sport and is inspiring change. With greater awareness, importance is being placed on selection of these athletes for sustainability, not just speed and stamina. Veterinary science is also improving, allowing earlier detection and more effective treatment of many of the common injuries. The combined effect of careful breeding selection and improved veterinary care will lead to better, stronger, healthier horses for the long term.



# Understanding Recurrent Airway Obstruction

## A look at typical symptoms and at home management

**R**ecurrent airway obstruction (RAO), also commonly referred to as “heaves,” is an allergic airway disease of horses. Horses affected with RAO have a reaction to inhaled dust, molds and endotoxins from hay and bedding. In affected horses, allergic airway excretions and spasm or narrowing of airways in the lungs makes breathing difficult. These animals experience collapse of the small airways during expiration, leading to increased effort during the expiratory phase of breathing.

It is important to recognize the early signs of RAO so that treatment and preventive measures can be initiated. Affected horses can have clinical signs that vary from mild to severe, including flared nostrils, chronic cough, nasal dis-

charge and respiratory impairment often including increased effort on expiration. Exercise intolerance is a common complaint. If the disease is severe enough, horses may develop a “heave line,” although that is not a common finding. A heave line is a distinct line of abdominal muscle enlargement that horses develop over time from increased breathing effort. Horses left untreated for RAO will develop permanent lung damage and severe exercise intolerance.

The diagnosis of RAO will be based upon a thorough history, a complete physical examination, routine blood work and broncho-alveolar lavage (BAL). A BAL involves passing an endoscope or a long tube into the patient’s lungs and collecting a sample of the cells from the lower airways.

One of the most important aspects of treatment for horses with RAO is at-home management. RAO is associated

with dusty environments and is seen most commonly in horses that are confined, fed hay (especially large round bales), are bedded with straw or live in a barn where hay is stored overhead.

Therefore, changes to the horse’s environment are critical. Horses with RAO should be turned out on pasture. Instead of feeding hay, a complete pelleted feed or hay cubes can be fed, which greatly decreases dust exposure. If hay must be fed, then it can be steamed or soaked. Hay should not be stored overhead and straw should not be used for bedding. These environmental changes are lifelong and are crucial to successful management of affected horses. Some horses present in a respiratory crisis from RAO and in those horses we are able to manage symptoms with medications, both systemic and inhaled, while the environmental changes have time to take effect.